

Leo Pažanin^{1,*},
 Hrvoje Čupić¹,
 Marko Radoš²,
 Hrvoje Jednačak³,
 Josip Paladino³

¹*Sestre milosrdnice University Hospital,
 Ljudevit Jurak University Department
 of Pathology,
 10000 Zagreb, Croatia*

²*Department of Radiology,
 School of Medicine, University of Zagreb,
 10000 Zagreb, Croatia*

³*Department of Neurosurgery,
 School of Medicine, University of Zagreb,
 10000 Zagreb, Croatia*

Received 10 January 2011
 accepted 25 February 2011

LIPOASTROCYTOMA: A CASE REPORT

Abstract

Lipidized tumours of the central nervous system are very rare. Lipidization of tumour cells is a histological hallmark of pleomorphic xanthoastrocytoma and cerebellar neurolipocytoma and has been described in some other primary neuroepithelial tumours such as glioblastoma, cerebral primitive neuroectodermal tumour, central neurocytoma and ependymoma. However, a few cases of lipidized low-grade glial tumours that could not be classified to the fore mentioned categories have been reported, as well. We report a new case of such a tumour occupying the right temporal lobe in a 23-year old woman. Histologically, the tumour was composed of GFAP positive glial cells with areas of complete cell lipidization. More than a two years after the surgery, the patient is well and asymptomatic supporting presumed favourable clinical course of these rare tumours. The recommended treatment plan for these presumably benignant tumours should be continued with radiographic surveillance after the gross total resection.

Keywords

Lipoastrocytoma • Lipidization • Glioma • Astrocytoma

© Versita Sp. z o.o.

CASE REPORT

One year before the surgery, the patient suffered minor head trauma and a CT scan was made that showed small hypodense lesion without contrast enhancement in the right temporal lobe. The MRI of the brain showed partially hypointense and isointense low-grade glioma in the right temporal lobe with a cortical presentation (Figure 1). In the meantime, the patient suffered an epileptic seizure that was controlled with an antiepileptic drug (Carbamazepine 2x200 mg). She was referred to the neurosurgeon who suggested a neurosurgical procedure. The surgery was performed in the supine position with the head slightly turned to the left side. After the right temporal craniotomy and dural opening, and using the neuronavigation system (Stealth Station Treon, Medtronic, USA) a hypovascular cortex with an apparent border between the tumour and the normal brain parenchyma was observed. The tumour was pale and grayish in colour and without any significant vascular structures. The cleavage

plane was very well defined and the tumour was extirpated totally. Postoperative course was uneventful. The patient was released from hospital 7 days after surgery without any neurological deficit. She had no seizures but remained on antiepileptic treatment with the tendency of gradual removal. Control neuroimaging follow-up showed no sign of residual or recurrent tumour.

Histologically, the tumour was a well-demarcated glioma composed of moderately pleomorphic cells. Different sized areas of completely lipidized and adipocyte-like, tumour cells were present throughout the tumour (Figure 2). The percentage of tumour cells showing lipidization was different in different tumour areas ranging from 40% to more than 80%. Granular bodies as morphological indicator of tumour benignancy were numerous while Rosenthal fibers were not observed. Mitotic activity was not found while Ki-67/Mib1 proliferation index was low (<1%). Microvascular proliferation and necrosis were not present in any of our sections. Immunohistochemically, tumour

cells, including lipidized ones, show strong and diffuse immunoreactivity for GFAP (Figure 3) and S100 protein, whereas synaptophysin, neurofilaments, p53 and IDH1 were negative. In lipidized cells GFAP immunoreactivity was noted in a thin cytoplasmic rim indicating their glial origin.

DISCUSSION

Lipidization is a well-known, although extremely rare, feature in primary neuroepithelial neoplasms of the central nervous system (CNS) [1]. Accumulation of multiple lipid droplets within the cytoplasm of tumour cells give rise to xanthomatous appearance of tumour cells while their coalescence into a single large droplet results in lipocyte-like cell morphology. Xanthomatous lipidization of tumour cells is a histologic feature of pleomorphic xanthoastrocytoma [2] and lipidized glioblastoma [3,4]. Lipomatous transformation of neoplastic cells has been described in cerebellar neurolipocytoma [5], and rare individual cases of ependymoma,

* E-mail: leo.pazanin@gmail.hr

central neurocytoma and cerebral primitive neuroectodermal tumour [1]. Lipomatous change in glial cells may be the result of anoxic or radiation injury and may reflect disturbed cellular metabolism or divergent differentiation rather than phagocytic activity or metaplasia [3].

However, a few cases of lipidized low-grade, otherwise non-specific, glial tumours have been reported, as well. Walter A et al. were first to report the case of a highly lipidized astrocytoma in a 77-year-old woman with a solid tumour mass in the right cerebellar hemisphere [6]. One year later, Roda and Gutierrez-Molina reported a case of multiple intraspinal, intramedullary and subarachnoidal, low-grade astrocytomas mixed with areas of randomly scattered adipose tissue in a 48-year-old woman and named these tumours "astrolipomas" [7]. However, only the astroglial component of this tumour showed glial fibrillary acidic protein (GFAP) immunoreactivity. So, this seems to be a collision tumour rather than lipidized astrocytoma. They tried to explain the multiple locations of this tumour by multifocality, glial meningeal heterotopia, and/or leptomeningeal spread. Their patient had no evidence of residual or recurrent disease more than one year after the surgery. Giangaspero et al. reported two cases of cerebral gliomas showing extensive lipidization of tumour cells and named these tumours "lipoastrocytomas" [1]. One tumour was occupying the temporal and occipital

lobes in a two-year-old girl and the other was a mural nodule in the left frontal lobe in twelve-year-old boy. Both patients were feeling well after a three and seven year follow-up, respectively, without any adjuvant treatment. Aryan et al. reported a case of solitary thoracic intramedullary astrolipoma with GFAP positive lipocytes [8]. Twelve months after the surgery, imaging revealed no evidence of a tumour. Finally, Gheri et al. described the last published case of a lipoastrocytoma involving

the upper part of the cerebellar-pontine angle and the right portion of the clivus starting from the brainstem in a 39 year-old man [9]. Their patient remains in a good neurological condition after ten months in spite of the fact that only subtotal excision of the tumour was accomplished and adjuvant chemotherapy and radiation therapy were not administered. Immunohistochemistry for GFAP and S-100 proteins proved the glial nature of lipid-laden cells. Ki-67/Mib-1 labelling index was low (2%).

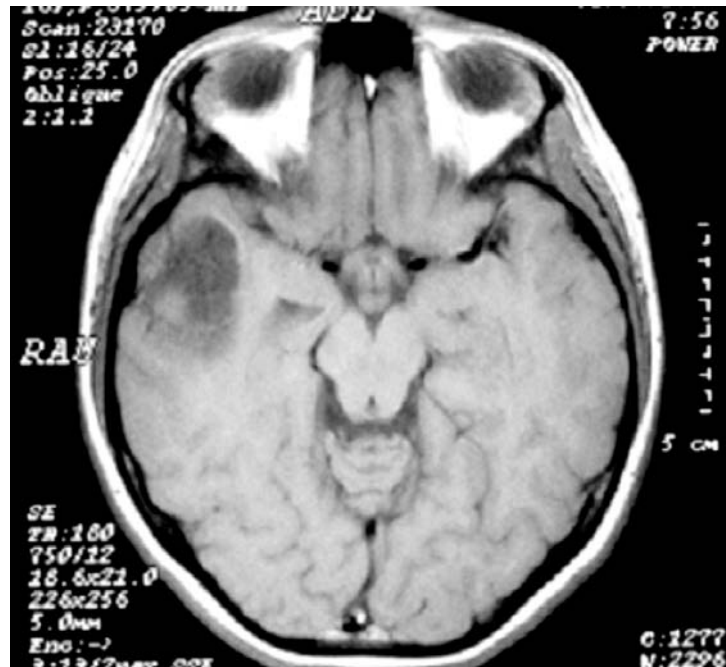

Figure 1. T1-weighted imaging with gadolinium enhancement MRI slice showing low-grade glioma which is partially hypo and partially isointense, occupying right temporal lobe with cortical presentation.

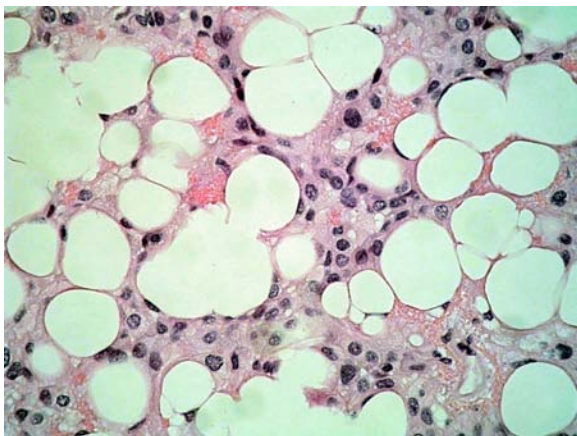


Figure 2. Histology shows a cellular glioma with widespread lipidization resulting in adipocyte-like cells (H&E, 400x).

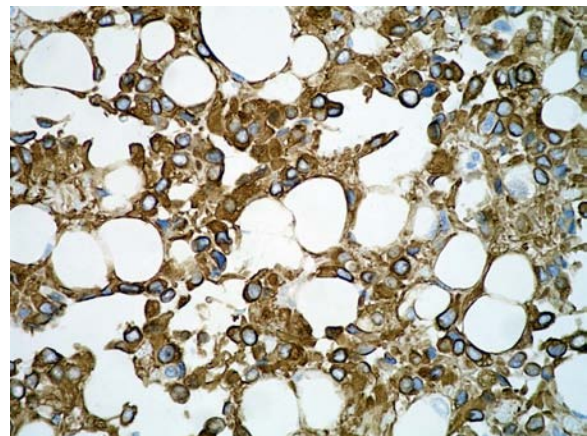


Figure 3. GFAP staining shows strong positivity of tumour cells (GFAP, 400x).

Owing to such a small number of cases reported it is not clear whether lipidized astroglomas constitute a distinct type of astrocytic neoplasm or not. Histological features and the molecular genetics results suggest that these tumours are distinct from the diffusely infiltrating astrocytomas, pilocytic astrocytomas and pleomorphic xanthoastrocytomas [1].

However, all these tumours seem to have in common low-grade histology and indolent biological behaviour with our case showing no difference in that respect.

Immunohistochemical positivity for GFAP of lipidized tumour cells in our case indicate lipomatous transformation of astroglial cells while low-grade histology was suggested by the presence of numerous eosinophilic granular bodies, absence of any mitotic activity and low proliferation potential. More than two years after the surgery, our patient was well and free of residual tumour or its recurrence.

In conclusion our case of lipidized, nonspecific, low-grade astroglioma further supports presumed benignant morphology

and favourable clinical course of these rare tumours. Based on these facts and the absence of p53 and IDH1 immunoreactivity we believe this is WHO grade I rather than WHO grade II glial tumour. Recommended treatment plan for these tumours based on their presumed benignancy should be continued radiographic surveillance after a gross total resection and resection for tumour recurrence. In order to better characterise and understand the biologic behaviour of this very rare tumour it is important to document each new case.

References

- [1] Giangaspero F., Kaulich K., Cenacchi G., Cerasoli S., Lerch K.D., Breu H. et al., Lipoastrocytoma: a rare low-grade astrocytoma variant of pediatric age, *Acta Neuropathol*, 2002, 103, 152-156
- [2] Kepes J.J., Pleomorphic xanthoastrocytoma: the birth of a diagnosis and a concept, *Brain Pathol*, 1993, 3, 269-274
- [3] Kepes J.J., Rubinstein L.J., Malignant gliomas with heavily lipidized (foamy) tumor cells: a report of three cases with immunoperoxidase study, *Cancer*, 1981, 47, 2451-2459
- [4] Rosenblum M.K., Erlandson R.A., Budzilovich G.N., The lipid-rich epithelioid glioblastoma, *Am J Surg Pathol*, 1991, 15, 925-934
- [5] Kleihues P., Chimelli L., Giangaspero F., Ohgaki H., Cerebellar liponeurocytoma. In: Louis D.N., Ohgaki H., Wiestler O.D., Cavenee W.K. (Eds.), *Pathology and genetics of tumours of the nervous system*, 4th ed., IARC Press, Lyon, 2000.
- [6] Walter A., Dingemans K.P., Weinstein H.C., Troost D., Cerebellar astrocytoma with extensive lipidization mimicking adipose tissue. *Acta Neuropathol* 1994, 88, 485-489
- [7] Roda J.M., Gutierrez-Molina M., Multiple intraspinal low-grade astrocytomas mixed with lipoma (astrolipoma). Case report, *J Neurosurg*, 1995, 82, 891-894
- [8] Aryan H.E., Imbesi S.G., Amjadi D.K., Abshire B.B., Intramedullary spinal cord astrolipoma: case report, *Neurosurgery*, 2003, 53, 985-988
- [9] Gheri C.F., Buccoliero A.F., Pansini G., Castiglione F., Garbini F., Moncini D., Maccari C., Mennonna P., Pellicanò G., Ammannati F., Taddei G., Lipoastrocytoma: case report and a review of the literature, *Neuropathology*, 2010, 30, 553-558