

Research Article

Engin Kölükçü*, Velid Unsal, Fatih Firat, Fikret Gevrek and Muzaffer Katar



Renoprotective effect of diacerein in rats with partial unilateral ureteral obstruction model

<https://doi.org/10.1515/tjb-2023-0237>

Received November 3, 2023; accepted February 9, 2024;

published online April 10, 2024

Abstract

Objectives: We aimed to analyze the effects of diacerein in a rat model of partial unilateral ureteral obstruction (PUUO).

Methods: We randomly divided 24 female rats into three groups. Control group, PUUO group and PUUO + diacerein group. The PUUO group was subjected to the PUUO model for seven days. The PUUO + diacerein group received oral diacerein (80 mg/kg) for seven days. Spectrophotometric methods were employed to measure oxidative stress parameters, including malondialdehyde (MDA), protein carbonyl (PC) and antioxidant enzyme levels, including glutathione peroxidase (GSH-Px), and superoxide dismutase (SOD), while indicators of renal function, such as kidney injury molecule-1 (KIM-1) and neutrophil gelatinous-associated lipocalin (NGAL), along with inflammatory parameters interleukin-1 beta (IL-1beta), tumor necrosis factor-alpha (TNF-alpha), and interleukin-6 (IL-6), were assessed using the ELISA method. Inflammatory parameters were measured in blood samples, and other parameters

were analyzed in kidney tissue. Hematoxylin-eosin method examinations were used for histological analyses.

Results: IL-1beta, TNF-alpha, and IL-6 levels were found to be significantly decreased in the PUUO + diacerein group compared to the PUUO group ($p=0.006$, $p=0.002$ and $p=0.001$, respectively). In the PUUO + diacerein group, GSH-Px and SOD activities increased compared with the PUUO group ($p=0.031$ and $p=0.037$, respectively). We also observed a significant improvement in renal function parameters, such as KIM-1 and NGAL levels in the PUUO + diacerein group compared to PUUO ($p=0.002$ and $p=0.012$, respectively). The PC and MDA levels were highest in the PUUO group ($p<0.001$). Similarly, the histopathologic tissue damage was the most prominent PUUO group ($p<0.001$).

Conclusions: Our study found that diacerein is a highly effective pharmacologic agent in alleviating oxidative damage in PUUO model rats.

Keywords: diacerein; partial ureteral obstruction; oxidative damage

Introduction

Obstructive uropathy causes oxidative stress associated with increased intraluminal pressure in the upper urinary tract [1]. It is a prominent cause of chronic renal failure, especially in infants and children. Obstructive uropathy is the etiologic factor in approximately half of pediatric patients with end-stage renal disease undergoing renal transplantation [2]. Ureteral obstructions may develop secondary to intraluminal or extraluminal pathologies. Many factors in the etiology include retroperitoneal fibrosis, malignancies, foreign bodies, urinary tract stone diseases, and abdominal surgeries [3]. Partial unilateral ureteral obstruction (PUUO) is a widespread pathology in the urology discipline [1, 3]. We have minimal knowledge about the pathophysiologic changes in the urinary system due to PUUO [2]. Impaired kidney blood flow, elevated intrapelvic pressure, vasoactive and inflammatory mediators such as transforming growth

***Corresponding author: Associate Professor Dr. Engin Kölükçü,** Department of Urology, Faculty of Medicine, Tokat Gaziosmanpaşa University, Karşıyaka mah.vali ayhan çevik caddesi, Seven Towers konutları Apt No: 12 D: 12, 60100, Merkez, Tokat, Türkiye, Phone: +535 400 23 85, Fax: +90 356 275 12 47, E-mail: drenginkolukcu@gmail.com. <https://orcid.org/0000-0003-3387-4428>

Velid Unsal, Mardin Artuklu University, Faculty of Health Sciences and Central Research Laboratory, Mardin, Türkiye, E-mail: velidunsal@gmail.com. <https://orcid.org/0000-0003-1415-0563>

Fatih Firat, Department of Urology, Tokat State Hospital, Tokat, Türkiye, E-mail: ffrat60@yahoo.com. <https://orcid.org/0000-0003-4283-1374>

Fikret Gevrek, Department of Histology and Embryology, Faculty of Medicine, Tokat Gaziosmanpaşa University, Tokat, Türkiye, E-mail: fikret.gevrek@gmail.com. <https://orcid.org/0000-0002-3722-2542>

Muzaffer Katar, Department of Biochemistry, Faculty of Medicine, Tokat Gaziosmanpaşa University, Tokat, Türkiye, E-mail: muzaffer.katar@gop.edu.tr. <https://orcid.org/0000-0002-6296-2390>

factor alpha, beta 2-microglobulin, and clusterin are the main factors involved in the pathophysiology of PUUO [3, 4]. Besides, recent studies have provided considerable evidence that reactive oxygen species (ROS) formed during PUUO play essential roles in this pathologic process [4]. It is documented that in previous experimental studies on rats with PUUO models, proinflammatory cytokine levels such as tumor necrosis factor-alpha (TNF-alpha) and interleukin-6 (IL-6) dramatically increased while tissue damage parameters such as malondialdehyde (MDA) and protein carbonyl (PC) elevated to extremely high levels [1, 4]. In this context, research has focused on pharmacologic agents containing antioxidant and anti-inflammatory properties to alleviate PUUO's harmful effects.

Diacerein (4,5-diacetoxy-9,10-dioxo-9,10-dihydroanthracene) is a pharmacologic agent mainly used for analgesic effects in the treatment of osteoarthritis [5, 6]. Its primary mechanism of action is described as an interleukin-1b (IL-1b) blocker [7]. Previous studies have revealed that rhein, the active metabolite of diacerein, has anti-inflammatory, antipyretic, antioxidant, and antitumor properties [5, 8]. Our research stands upon the hypothesis of detailing the specifications of possible nephroprotective peculiarities of this pharmacological agent against secondary renal damage on PUUO based on cytoprotective properties. In this context, the pharmacological efficacy of diacerein has been analyzed in many different systems, such as the liver, testis, and kidney, in the ischemia-reperfusion model [9]. There is a minimal number of studies in the literature regarding the protective effect of diacerein on kidney tissue. Through these limited studies, diacerein has been documented to minimize oxidative stress on renal injury models caused by nephrotoxic agents [6]. In our study, the effect of diacerein on kidney tissue was analyzed in detail using the PUUO model.

This experimental study aimed to evaluate diacerein's possible renoprotective activity in a rat PUUO model. To our knowledge, this is the first study in which diacerein was applied in the PUUO model.

Materials and methods

All experimental interventions were approved by the Animal Experiments Local Ethics Gaziosmanpa  a University (HADYEK 2021-5). Our study included 24 female Albino-Wistar rats (230–410 g, 12–14 weeks old). We experimented with a constant temperature ($22 \pm 2^\circ\text{C}$) with a 12-h light/dark cycle.

Surgical procedure

All surgical interventions were performed under sterile conditions with xylazine/ketamine anesthesia. Sterile saline was administered at the rate of 5 % of body weight by catheterizing the right femoral vein to replace the fluid lost until the end of the procedure.

Control group: These rats underwent laparotomy through the midline incision of the abdomen. Their ureters were manipulated but not ligated. Approximately 5 mL of blood samples were taken from the inferior vena cava of the rats in this group for biochemical analysis. In addition, left nephrectomy was performed for biochemical analysis and histopathological examinations [2, 3].

PUUO group: A midline incision was made as previously described in the literature, and the left ureter was exposed over the left psoas muscle. Two-thirds of the left ureter was embedded in the psoas muscle with 4-0 non-absorbable sutures. After seven days, approximately 5 mL of blood samples were taken from the inferior vena cava of the rats in this group for biochemical analysis. In addition, left nephrectomy was performed for biochemical analysis and histopathological examinations [3].

PUUO + diacerein group: This group was designated as the treatment group and established similarly to the PUUO model in the PUUO group. In addition, diacerein 80 mg/kg was administered to the rats in this group by oral gavage once a day for seven days [10].

Histopathologic examination

At the end of the experiment, the kidneys were placed directly in a 4 % buffered neutral formalin solution and fixed for three days for histological analysis. The blocked kidneys were sectioned, and consecutive thin serial sections of 5 μm thickness were taken. The renal tissue sections were placed on frozen slides for hematoxylin and eosin staining and prepared for histopathologic analysis to detect tissue damage. Renal tissues of the study groups were analyzed under a 40 \times objective with a research light microscope (Nikon, Eclipse, 200; Japan). Renal tissue section specimens were evaluated for overall tissue integrity, parenchymal and stromal damage, tubular integrity, necrosis, and congestion and graded semiquantitatively from 1 to 4. Accordingly, 1 (none) means there is no damage; 2 indicates mild damage (epithelial flattening, tubule dilatation, nuclear dropout, and loss of brush border); 3 is moderate damage (focal coagulative type necrosis); and 4 (infarction) is a sign of severe damage [11].

Preparation of kidney tissues for biochemical analysis

Tissues were washed with cold normal saline solution and weighed to prepare homogenate and supernatant. With the help of a homogenizer, 10 % homogenates were formed with pH 7.4 Tris-HCl phosphate buffer solution (1:10). The MDA level was measured in some homogenates without any process. The remaining homogenates were centrifuged at 4,000 rpm at 4°C for 15 min, and the supernatant was analyzed for PC levels and glutathione peroxidase (GSH-Px) and superoxide dismutase (SOD) activities.

Measurement of SOD and GSH-Px activity in tissues

SOD enzyme activity was analyzed by the method modified by Sun et al., while GSH-Px activity was analyzed according to the method of Paglia et al. The enzyme activity of both methods was expressed as U/g protein [12, 13].

Measurement of MDA and PC levels in tissues

While the study was performed according to the Esterbauer method, the measurement method of lipid peroxidation, protein carbonyl content in the tissue was examined by the method based on the reaction of the carbonyl group to form 2,4-dinitrophenylhydrazine 2,4-(DNPH) [14, 15].

Protein quantification in tissues

Protein contents of all homogenates and supernatants were analyzed according to the Folin-Lowry method et al. [16].

Measurements of proinflammatory cytokines

TNF-alpha (BTLab, Code: E0764Ra, Lot No: 202104006), IL-1beta (BTLab, Code: E0119Ra, Lot No: 202104006) and IL-6 (BTLab, Code: E0135Ra, Lot No: 202104006) parameters were studied from serum samples obtained from the blood of rats.

Assessment of renal function

Neutrophil gelatinous-associated lipocalin (NGAL, BTLab, Code: E0762Ra, Lot No: 202104006) and kidney injury molecule-1 (KIM-1, BTLab, Code: E0549Ra, Lot No: 202104006) were assayed from renal homogenized with a homogenizer with 0.01 N pH=7.2–7.4 phosphate buffer and then from the supernatants obtained after centrifugation at 4,000 rpm for 15 min at 4 °C. All ELISA kits were provided by Atlas Biyoteknoloji

(Ankara, Turkey), and the measurement methods were performed as described in the package inserts of the ELISA kits. The amount of protein in the supernatants was also measured as previously described [16].

Statistical analysis

Descriptive statistics were used to provide information about the general characteristics of the study groups. The measured data of the variables were described using mean and standard deviation ($\bar{x} \pm SD$) (mean values \pm standard deviation). Differences between groups were evaluated by One-Way Analysis of Variance (ANOVA) by assessing the homogeneity of variances. Post-hoc Tukey HSD or Tamhane's T2 was used for pairwise comparisons. p-Values less than 0.05 were considered statistically significant. Off-the-shelf statistical software was used for calculations (IBM SPSS Statistics 26, SPSS Inc., an IBM Co., Somers, NY).

Results

Tables 1 and 2 document our biochemical analysis results.

Effect of diacerein on oxidative stress in renal tissue

SOD and GSH-Px activities were reported as 39.0 ± 8.84 U/g protein and 5.24 ± 0.78 U/g protein in the PUUO + diacerein group, respectively, which were higher compared to the PUUO group ($p=0.037$ and $p=0.031$, respectively). MDA and PC levels, end products of lipid peroxidation and protein oxidation, were calculated as 9.04 ± 1.55 nmol/g wet tissue and 1.75 ± 0.40 nmol/mg protein in the PUUO group. There was a dramatic decrease in these values in the PUUO + diacerein group ($p=0.010$ and $p=0.003$, respectively).

Table 1: Effect of diacerein on renal function and oxidative stress levels.

Parameters	Groups			p-Value
	Control (n=8)	PUUO (n=8)	PUUO + diacerein (n=8)	
SOD, U/g protein	47.5 ± 16.4^a	27.4 ± 5.48^b	39.0 ± 8.84^a	0.006
GSH-PX, U/g protein	6.88 ± 1.49^a	4.22 ± 0.77^b	5.24 ± 0.78^c	<0.001
MDA, nmol/g wet tissue	5.46 ± 0.87^a	9.04 ± 1.55^b	6.72 ± 0.74^c	<0.001
PC, nmol/mg protein	0.76 ± 0.23^a	1.75 ± 0.40^b	1.15 ± 0.30^a	<0.001
KIM-1, ng/protein	4.32 ± 1.34^a	8.02 ± 1.17^b	5.23 ± 1.13^a	<0.001
NGAL, ng/protein	20.9 ± 6.40^a	38.8 ± 9.54^b	24.9 ± 4.74^a	<0.001

Values are expressed as mean \pm SD. One-Way Analysis of Variance (ANOVA) was used for multigroup comparisons. Differences between groups were examined with *post hoc* Tukey HSD or Tamhane's T2. p-Value less than 0.05 were considered significant and highlighted in bold. Different lowercase letters (a,b,c) in the same line indicate a statistically significant difference ($p<0.05$) between the groups by post-hoc analysis. GSH-PX, glutathione peroxidase; KIM-1, kidney injury molecule-1; MDA, malondialdehyde; NGAL, neutrophil gelatinous-associated lipocalin; PC, protein carbonyl; PUUO, partial unilateral ureteral obstruction; SOD, superoxide dismutase. Repeatability before ANOVA was calculated with the F test for each variable. Accordingly, F test values were 3.42 for SOD, 3.70 for GSH-PX, 3.17 for MDA, 3.01 for PC, 1.40 for KIM-1, and 2.22 for NGAL. Since our T table value in the relevant degree of freedom is calculated as 3.79, all F test values of our variables are below this value. The variables are suitable for repeatability.

Table 2: Effect of diacerein on proinflammatory cytokine levels.

Parameters	Groups			p-Value
	Control (n=8)	PUUO (n=8)	PUUO + diacerein (n=8)	
TNF alpha, ng/L	498 ± 88.7 ^a	763 ± 113 ^b	589 ± 56 ^a	<0.001
IL-1beta, pg/ml	595 ± 82.1 ^a	764 ± 77.7 ^b	632 ± 65.1 ^a	0.001
IL-6, ng/L	10.4 ± 1.81 ^a	17.6 ± 2.75 ^b	12.9 ± 1.66 ^a	<0.001

Values are expressed as mean ± SD. One-Way Analysis of Variance (ANOVA) was used for multigroup comparisons. Differences between groups were examined with *post hoc* Tukey HSD or Tamhane's T2. p-Value less than 0.05 were considered significant and highlighted in bold. Different lowercase letters (a,b) in the same line indicate a statistically significant difference (p<0.05) between the groups by post-hoc analysis. IL-1beta, interleukin-1 beta; IL-6, interleukin-6; PUUO, partial unilateral ureteral obstruction; TNF alpha, tumor necrosis factor-alpha. Repeatability before ANOVA was calculated with the F test for each variable. Accordingly, F test values were 1.62 for TNF-alpha, 1.59 for IL-1beta, and 2.74 for IL-6. Since our T table value in the relevant degree of freedom is calculated as 3.79, all F test values of our variables are below this value. The variables are suitable for repeatability.

Effect of diacerein on renal function

Renal function markers, KIM-1, and NGAL levels improved significantly in the PUUO + diacerein group compared to the PUUO group (p=0.002 and p=0.012, respectively).

Effect of diacerein on proinflammatory cytokine levels

In PUUO group, TNF-alpha, IL-1beta, and IL-6 levels were 763 ± 113 ng/L, 764 ± 77.7 pg/mL, and 17.6 ± 2.75 ng/L, respectively. All these proinflammatory cytokine levels decreased in the PUUO + diacerein group compared to the PUUO group (p=0.002, p=0.006, and p=0.001, respectively).

Effect of diacerein on renal damage

In the PUUO group, we observed marked epithelial flattening, tubular dilatation and irregularities, nuclear detachment/separation, loss of brushy edge, focal coagulative necrosis, glomerular deformities, local tissue erosions/losses, and diffuse congestion areas (Figure 1). Rats in this group had 3.13 renal injury scores. PUUO + diacerein group had a significant improvement in tissue damage parameters, and the renal injury score was 2.02 (p<0.001).

Discussion

This experimental study documented that diacerein treatment in PUUO showed renoprotective activity biochemically and histopathologically. The data obtained in our study demonstrated a decrease in MDA and PC levels, which are directly related to the increased oxidative stress level after PUUO following diacerein treatment. Similarly, we observed

decreased proinflammatory cytokine levels such as IL-1beta, TNF-alpha, and IL-6. On the other hand, there was a significant increase in the activities of GSH-Px and SOD. In addition, we noted that renal function level improved after diacerein treatment, and tissue damage in parenchymal, stromal, and tubular structures regressed histopathologically.

Obstructive nephropathy is not a primitive mechanical disorder of the urine system but a complex phenomenon that causes glomerular hemodynamic and tubular functional changes [17]. The pathophysiology of urinary tract obstruction includes impaired renal blood flow, increased renal pressure, and ischemic atrophy [2, 17]. ROS also plays an important role in renal damage. During urethral obstruction, renal flow is impaired, and a large amount of oxygen enters the environment with the refusion of tissues after treatment. Superoxide anions increase in tissue end products through a series of reactions in which xanthine dehydrogenase plays a key role [8].

However, in addition to the decreased antioxidant reserve in the obstructive kidney, highly increased ROS levels show destructive effects on membrane lipids, carbohydrates, proteins, and other molecules [2]. Demirbilek et al. reported decreased antioxidant levels and increased oxidative stress products in the obstructive kidney [18]. Yasar et al. observed an increase in MDA and nitric oxide levels in the PUUO-induced rat model compared to the control group [3]. Similarly,   zt  rk et al. observed decreased SOD, GSH-Px, and catalase activities and increased MDA levels in PUUO-induced rats [2]. We observed a decrease in antioxidant enzymes (SOD and GSH-Px activities), and a significant increase in PC and MDA levels, which are markers of protein and lipid metabolism damage markers, in the PUUO model-induced rat group. In addition, ROS causes serious damage to the cell membrane through lipid peroxidation reactions and contributes significantly to tubulointerstitial inflammation [1, 4]. Wang et al. reported that a unilateral ureteral obstruction mice model caused a significant increase in

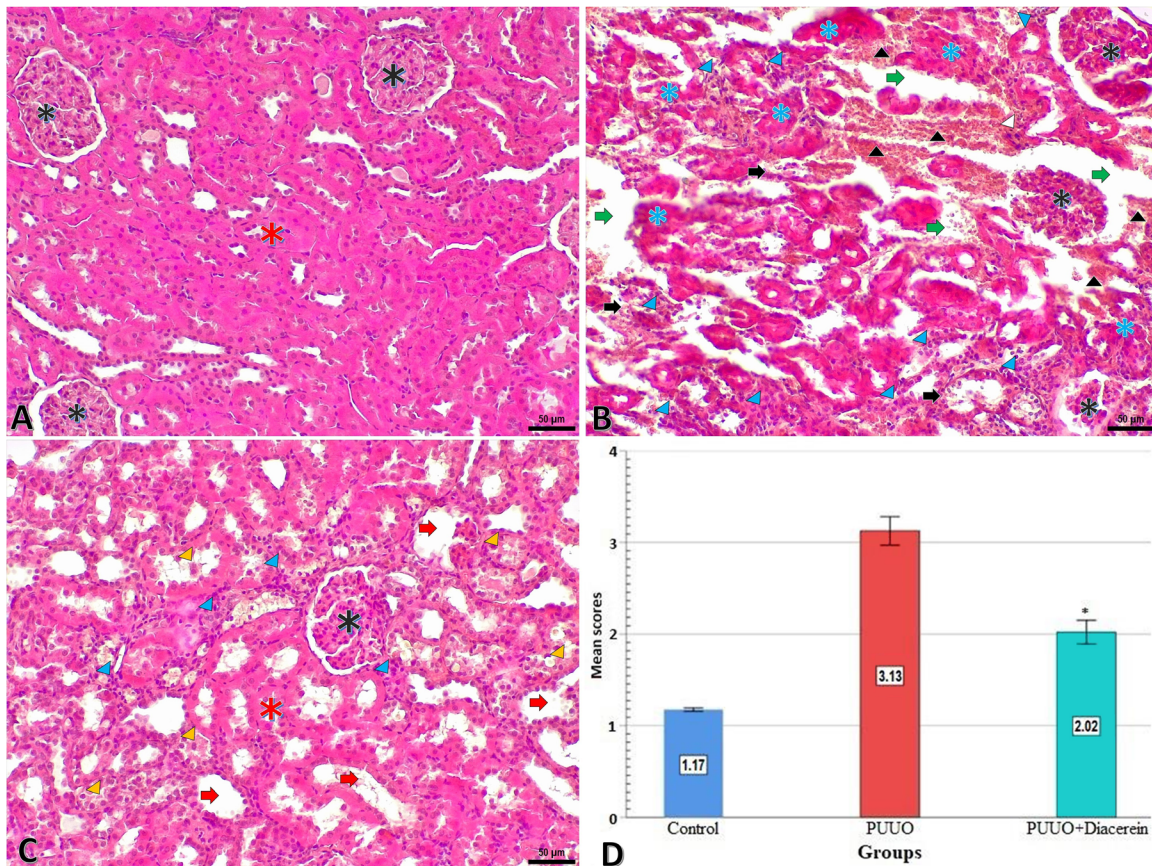


Figure 1: Representative microscopic images of kidneys from the study groups (A) control group; (B) PUUO group; (C) PUUO + diacerein group) and (D) graphical display of group mean values of tissue damage scores. Kidney tissue with a regular histologic arrangement of glomerular (black star) and tubular (red star) structures without tissue damage is seen in picture A. Picture B shows kidney tissues with severe tissue damage, such as deformed glomerular (black star) and tubular (blue star) structures, congestion and intense hemorrhage (black arrowhead), ischemia (black arrow), areas of parenchymal and stromal tissue erosion (green arrow), inflammatory cell infiltration (blue arrowhead). The damage score of this group is the highest of the others. In picture C, renal tissues with glomerular (black star) and tubular (red star) structures in generally normal histological order, although there are mild tissue damages, including tubular dilatation (yellow arrow), tubular apoptotic cells and epithelial debris (yellow arrowhead), some areas of inflammation (blue arrowhead). Tissue damage is lower in this group than in the PUUO group. (Hematoxylin-eosin, Scale bar=50 μ m). The graphical image is a comparative display of the tissue damage score values. Different colors of the graph columns indicate that each group is statistically different from each other ($p < 0.001$). PUUO, partial unilateral ureteral obstruction.

myeloperoxidase activity and inflammatory cytokine levels in rats [19]. Similarly, Ozbek et al. documented intense leukocyte infiltration in the periglomerular and peritubular interstitium with unilateral ureteral obstruction [20]. We observed severe inflammatory infiltration areas in our histopathologic specimens in rats with PUUO. Besides, there was a significant increase in proinflammatory levels such as IL-1 β , IL-6, and TNF- α . Increased oxidative stress in PUUO is closely associated with tubulointerstitial lesions and renal fibrosis [1, 20]. It is crucial to keep the ROS level under control to minimize the harmful effects of PUUO. Increasing antioxidant levels and suppressing inflammation are essential [2, 3].

Diacerein is an anthraquinone derivative [21, 22]. Its primary mechanism of action is the inhibition of the IL-1 signaling pathway. In addition, different studies have reported an inhibitory effect of this pharmacological agent on IL-6 and TNF- α . In addition to these potent anti-inflammatory properties, diacerein has anti-apoptotic and antioxidant properties [21]. Previous studies have analyzed the efficacy of diacerein in different medical disciplines, such as nephroprotective, hepatoprotective, anti-neuropathic pain, intervertebral disc degeneration, anti-ulcerative colitis, thyroid dysfunction, testicular damage, epidermolysis bullosa, antinociceptive effect, insulin sensitivity, and glycemic control [9].

The renoprotective efficacy of diacerein has not been fully elucidated. Tubular epithelial cell apoptosis plays a significant role in the pathogenesis of acute kidney injury. Diacerein reverses the direction of the apoptotic balance by reducing renal Bax levels, thereby improving apoptosis. On the other hand, the proinflammatory response plays a key role in acute kidney injury. Diacerein suppresses inflammation by inhibiting the synthesis of IL-1 β . Simultaneously, it alters tubular water and sodium transport, leading to a reduction in kidney inflammation and an improvement in kidney functions. However, insufficient levels of antioxidant enzymes exacerbate renal damage. Diacerein contributes to its renoprotective efficacy by increasing endogenous antioxidant enzyme levels [6, 22]. There is a limited number of studies evaluating the renoprotective activity of diacerein. Abd-Elattifa et al. evaluated the efficacy of diacerein against glycerol-induced renal injury and documented that diacerein attenuated oxidative damage with anti-apoptotic, antioxidant, anti-necroptotic, and anti-inflammatory effects [6]. A similar study by Refaie et al. evaluating the efficacy of diacerein in doxorubicin-induced nephrotoxicity in rats reported that diacerein suppressed oxidative stress, inflammation, and tissue damage. The study details showed that diacerein also demonstrated antioxidant activity by increasing SOD, glutathione (GSH), and catalase in rat groups [23]. Similar to this activity, Refaie et al. reported that diacerein showed antioxidant activity by increasing SOD activity in cervical hyperkeratosis [7]. Abdel-Gabera et al. reported that diacerein also caused antioxidant activity by increasing GSH and SOD activities in testicular oxidative damage [8]. Ischemia-reperfusion injury causes hydrogen peroxide to be cleaved into hydrogen and oxygen free radicals, thereby disrupting defense mechanisms by destroying biological molecules such as amino acids, nucleic acids, and cell membranes [24, 25]. In this context, antioxidant defense mechanisms are critical in ischemia-reperfusion injury [26]. Our study observed a statistically significant increase in GSH-Px and SOD activities in the diacerein treatment group compared to the PUUO group.

Increased inflammatory response increasingly potentiates oxidative stress, leading to organ dysfunction. For this reason, suppressing inflammation in tissue subjected to ischemia-reperfusion injury is extremely important [24]. Barakat et al. observed that diacerein caused a significant decrease in transforming growth factor beta-1 levels in the kidney and improved renal function in cisplatin-induced nephrotoxicity [27]. In another study evaluating cisplatin-induced nephrotoxicity, Abdel-Aziz et al. concluded that diacerein improved oxidative stress in kidney tissue by reducing TNF- α levels [28]. In a similar study, Taha et al. observed that diacerein decreased IL-1 β immune

expression in renal ischemia-reperfusion injury and alleviated renal damage by suppressing renal inflammation [29]. Tamura et al. reported that diacerein blocked the production of reactive oxygen radicals due to inhibition of neutrophil activation in a model of gastric ulceration [22]. In our study, we observed that IL-1 β , TNF- α , and IL-6 decreased in the diacerein-treated group and, at the same time, inflammatory cell infiltration regressed in tissue histopathologic samples.

Diacerein has long been used safely and widely worldwide [9]. The average elimination half-life is around 7–8 h [30]. Diacerein is reported to have a limited risk of skin and gastrointestinal side effects. Considering the risk of gastrointestinal disorders, the laxative effect of diacerein due to its anthraquinone chemical structure is quite common. Large series studies report a 24 % absolute increase in the risk of patients experiencing diarrhea compared to placebo. The incidence of cutaneous reactions associated with diacerein ranges from 1.8 to 9.4 %. Rash, pruritus, and eczema are the most commonly observed dermatological problems associated with this pharmacologic agent. There are limited adverse effects on the liver. The most commonly observed liver pathology is a moderate increase in liver enzymes without bilirubin increase [30]. On the other hand, diacerein has no gastrointestinal bleeding or cardiac, renal, or hematologic toxicity effects [5, 29].

Our study's most prominent limitation is evaluating diacerein's possible side effect profile in rats. Other limitations are the inability to perform detailed immunohistochemical staining due to technical shortcomings and the inability to calculate the glomerular filtration rate.

In conclusion, our study was the first in the English literature to evaluate the efficacy of diacerein in rats with the PUUO model. According to the data obtained in our study, diacerein is a highly effective pharmacologic agent in suppressing inflammation secondary to PUUO, improving oxidative damage, and protecting renal function. Our study needs extensive randomized studies to guide routine urology practice.

Research ethics: All institutional and national guidelines for the care and use of laboratory animals were followed and approved by the appropriate institution (Gaziosmanpa  a University Animal Experiments Local Ethics Committee, HADYEK 2021-5).

Informed consent: Not applicable.

Author contributions: Study conception and design: Engin Kolukcu, Fatih F  rat, Fikret Gevrek, Velid Unsal, Muzaffer Katar. Acquisition of data: Engin Kolukcu, Velid Unsal, Muzaffer Katar, Fikret Gevrek. Analysis and interpretation of data: Engin Kolukcu, Velid Unsal, Fatih F  rat Muzaffer

Katar. Drafting of manuscript: Engin Kolukcu, Muzaffer Katar, Fatih Firat. Critical revision: Engin Kolukcu, Muzaffer Katar, Fatih Firat, Velid Unsal, Fikret Gevrek. All authors have accepted responsibility for the entire content of this manuscript and approved its submission.

Competing interests: Authors state no conflict of interest.

Research funding: None declared.

Data availability: The raw data can be obtained on request from the corresponding author.

References

1. Sancak EB, Tan YZ, Turkon H, Silan C. Attenuation of partial unilateral ureteral obstruction-induced renal damage with hyperbaric oxygen therapy in a rat model. *Int Braz J Urol* 2017;43:946–56.
2. Ozturk H, Firat T, Tekce BK, Yilmaz F, Ozturk H. Effects of nicorandil on renal function and histopathology in rats with partial unilateral ureteral obstruction. *Kaohsiung J Med Sci* 2017;33:236–45.
3. Yasar A, Erdemir F, Parlaktas BS, Atilgan D, Koseoglu RD, Saylan O, et al. The effect of carvedilol on serum and tissue oxidative stress parameters in partial ureteral obstruction induced rat model. *Kaohsiung J Med Sci* 2013;29:19–25.
4. Atilgan D, Parlaktas BS, Uluocak N, Erdemir F, Firat F, Erkorkmaz U, et al. Effects of melatonin on partial unilateral ureteral obstruction induced oxidative injury in rat kidney. *Urol Ann* 2012;4:89–93.
5. Pavelka K, Bruyère O, Cooper C, Kanis JA, Leeb BF, Maheu E, et al. Diacerein: benefits, risks and place in the management of osteoarthritis. An opinion-based report from the ESCO. *Drugs Aging* 2016;33:75–85.
6. Abd-Elattifa RN, Hegabb II, Atefa MM, Sadek MT, Hafez YM. Diacerein protects against glycerol-induced acute kidney injury: modulating oxidative stress, inflammation, apoptosis and necroptosis. *Chem Biol Interact* 2019;306:47–53.
7. Refaie MM, El-Hussieny M. Diacerein inhibits estradiol-benzoate induced cervical hyperkeratosis in female rats. *Biomed Pharmacother* 2017;95:223–9.
8. Abdel-Gabera SA, Mohammed RK, Refaie MMM. Mechanism mediating the protective effect of diacerein in ischemia-reperfusion-induced testicular injury in rats. *Life Sci* 2018;209:57–62.
9. Almezgagi M, Zhang Y, Hezam K, Shamsan E, Gamah M, Al-Shaebi F, et al. Diacerein: recent insight into pharmacological activities and molecular pathways. *Biomed Pharmacother* 2020;131:110594.
10. Torina AG, Reichert K, Lima F, Vilarinho KAS, Oliveira PPM, Carmo HRP, et al. Diacerein improves left ventricular remodeling and cardiac function by reducing the inflammatory response after myocardial infarction. *PLoS One* 2015;10:e0121842.
11. Liapis H, Gaut JP, Klein C, Bagnasco S, Kraus E, Farris AB, et al. Banff histopathological consensus criteria for preimplantation kidney biopsies. *Am J Transplant* 2017;17:140–50.
12. Sun Y, Oberley LW, Li YA. Simple method for clinical assay of superoxide dismutase. *Clin Chem* 1988;34:497–500.
13. Paglia DE, Valentine WN. Studies on the quantitative and qualitative characterization of erythrocyte glutathione peroxidase. *J Lab Clin Med* 1967;70:158–69.
14. Esterbauer H, Cheeseman KH. Determination of aldehydic lipid peroxidation products: malonaldehyde and 4-hydroxynonenal. *Methods Enzymol* 1990;186:407–21.
15. Levine RL, Garland D, Oliver CN, Amici A, Climent I, Lenz AG, et al. Determination of carbonyl content in oxidatively modified proteins. *Methods Enzymol* 1990;186:464–78.
16. Lowry OH, Rosebrough NJ, Farr AL, Randall RJ. Protein measurement with the Folin phenol reagent. *J Biol Chem* 1951;193:265–75.
17. Sinik Z, Turan T, Demir S, Yilmaz U, Sert S, Aybek Z. The effect of partial unilateral ureteral obstruction release and allopurinol on the renal malondialdehyde and glutathione levels. *Int J Urol* 2005;12:990–3.
18. Demirbilek S, Emre MH, Aydin EN, Edali MN, Aksoy RT, Akin M, et al. Sulfasalazine reduces inflammatory renal injury in unilateral ureteral obstruction. *Pediatr Nephrol* 2007;22:804–12.
19. Wang Y, Wang B, Du F, Su X, Sun G, Zhou G, et al. Epigallocatechin-3-gallate attenuates oxidative stress and inflammation in obstructive nephropathy via NF- κ B and Nrf2/HO-1 signalling pathway regulation. *Basic Clin Pharmacol Toxicol* 2015;117:164–72.
20. Ozbek E, Ilbey YO, Ozbek M, Simsek A, Cekmen M, Somay A. Melatonin attenuates unilateral ureteral obstruction-induced renal injury by reducing oxidative stress, iNOS, MAPK, and NF- κ B expression. *J Endourol* 2009;23:1165–73.
21. Oliveira PG, Termini L, Durigon EL, Lepique AP, Sposito AC, Boccardo E. Diacerein: a potential multi-target therapeutic drug for COVID-19. *Med Hypotheses* 2020;144:109920.
22. Tamura T, Yokoyama T, Ohmori K. Effects of diacerein on indomethacin-induced gastric ulceration. *Pharmacology* 2001;63:228–33.
23. Refaie MMM, Amin EF, El-Tahawy NF, Abdelrahman AM. Possible protective effect of diacerein on doxorubicin-induced nephrotoxicity in rats. *J Toxicol* 2016;2016:9507563.
24. Ibrahim MA, Abdelzاهر WY, Ibrahim YF, Ahmed AF, Welson NN, Al-Rashed S, et al. Diacerein protects rats with liver ischemia/reperfusion damage: down-regulation of TLR4/NF- κ B signaling pathway. *Biomed Pharmacother* 2021;134:111063.
25. Kölükçü E, Parlaktas BS, Kölükçü V, Firat F, Deresoy FA, Katar M, et al. Protective effects of dexmedetomidine on ischaemia-reperfusion injury in an experimental rat model of priapism. *Andrologia* 2021;53:13985.
26. Yalçın K, Ersoy E. Activity of Diosmin-Hesperidin in kidney ischemia-reperfusion injury in rats: experimental study. *Grand J Urol* 2024;4:12–8.
27. Barakat N, Barakat LAA, Zakaria MM, Khirallah SM. Diacerein ameliorates kidney injury induced by cisplatin in rats by activation of Nrf2/Ho-1 pathway and Bax down-regulation. *Saudi J Biol Sci* 2021;28:7219–26.
28. Abdel-Aziz AM, Ibrahim MA, El-Shiekh AA, Osman NA, Geddawy A, Abdelrahman A. Prophylactic effect of diacerein against cisplatin-induced nephrotoxicity in rats. *Int J Pharmacol* 2018;14:384–90.
29. Taha M, Ibrahim MM, Elazab ST, Badawy AM, Abdelsalam RA, Saati AA, et al. Diacerein mitigates renal ischemia/reperfusion injury via inhibition of renal inflammation, dendritic cells maturation and apoptosis: the role of TLR4/NF- κ B/NLRP3/IL-1 β signaling pathway. *Int. Morphol* 2023;41:625–33.
30. Nicolas P, Tod M, Padoin C, Petitjean O. Clinical pharmacokinetics of diacerein. *Clin Pharmacokinet* 1998;35:347–59.