

Alina Weissmann-Brenner*, Yinon Gilboa, Gil M. Yerushalmi, Reuven Achiron and Eyal Schiff

Sonographic presentations of uterine rupture following vaginal birth after cesarean – report of two cases 12 h apart

Abstract: We present two patients who delivered vaginally following a prior cesarean section in whom uterine rupture was detected a few minutes after delivery. Both deliveries occurred within 12 h. The sonographic findings were different in each case and consistent with the clinical and operative findings. Ultrasound may assist in the diagnosis of uterine rupture following delivery.

Keywords: Cesarean section; laparotomy; ultrasound; uterine rupture; vaginal birth after cesarean (VBAC).

*Corresponding author: Alina Weissmann-Brenner, Department of Obstetrics and Gynecology, Chaim Sheba Medical Center, Tel Hashomer, Israel, Tel.: +972-3-5306118, Fax: +972-3-5303168, E-mail: alinabrenner@yahoo.com

Yinon Gilboa, Gil M. Yerushalmi, Reuven Achiron and Eyal Schiff: Department of Obstetrics and Gynecology, Chaim Sheba Medical Center, Tel Hashomer, Israel

Introduction

Uterine rupture is an uncommon obstetrical event associated with severe maternal and perinatal morbidity and mortality. The most common cause of uterine rupture is separation of a previous cesarean scar [2, 5, 6]. The diagnosis is based mainly on clinical examination consisting of maternal hypovolemic shock, chest pain due to irritation of the diaphragm from the hemoperitoneum, and severe fetal decelerations or bradycardia. There is little use of ultrasound in this emergent situation; hence, there is little information regarding the sonographic appearance of the ruptured uterus.

We present the sonographic demonstration of uterine rupture in two patients who delivered vaginally following a prior cesarean section (VBAC) in whom uterine rupture was detected a few minutes after delivery. Both deliveries took place in our hospital within 12 h.

Case 1

A 35-year-old gravida (G) 5 para (P) 3 woman was admitted to the delivery room with uterine contraction and rupture of membranes at 39.5 weeks' gestation. Her obstetrical history consisted of two vacuum extractions at G1 and G2 at term, and a low transverse cesarean section at term at G3 owing to suspected macrosomia without complications.

On admission, her physical examination was unremarkable with soft, non-tender uterus without tenderness on the uterine scar, and without bleeding. Her cervix was dilated to 1.5 cm, 50% effaced, with the fetal head at S-3. She was admitted to the labor room and progressed spontaneously without oxytocin to full dilatation and normal vaginal delivery. The fetal monitor consisted of a baseline of 140 bpm, accelerations, and good variability. In the last 10 min of labor, at full dilatation and during maternal pushing, moderate variable decelerations appeared that preserved good variability, and she gave birth spontaneously to a male neonate of 3300 g, with Apgar scores of 9 and 10 at 1 and 5 min, respectively. Following delivery of the placenta, she felt weak and dizzy. No abnormal vaginal bleeding was present. Her vital signs were normal. Manual revision of the uterus revealed a deficit in the anterior wall of the uterus. Abdominal ultrasound demonstrated a hypoechogenic area at the uterine scar (Figure 1) with moderate amount of fluid in the abdomen.

The patient was immediately taken to the operation room for explorative laparotomy through the previous Pfannenstiel scar. About 1000 mL of blood was present in the abdomen. Complete rupture of the uterus starting at the middle of the previous scar extending downward to the cervix and the vagina, with rupture of the urinary bladder, was observed. All the ruptures were repaired. Blood products were given during the operation. Her follow-up was unremarkable, and she was discharged 5 days after the operation.

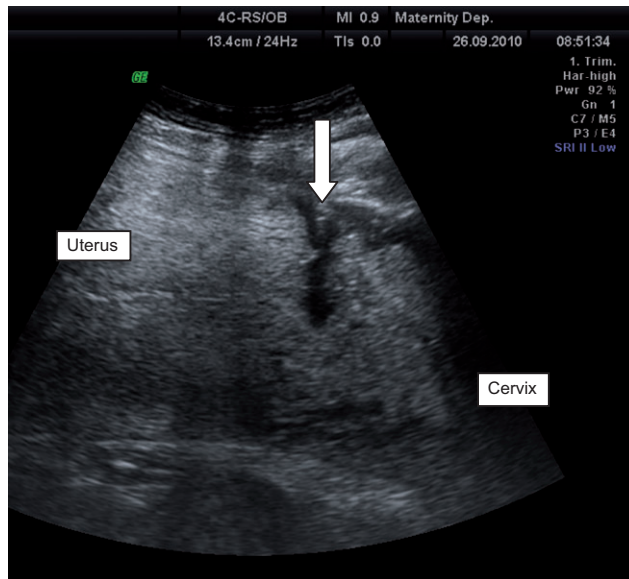


Figure 1 Two-dimensional ultrasound of the uterus demonstrating a hypoechoic area at the lower uterine segment (arrow), representing bleeding through uterine rupture into the abdomen.

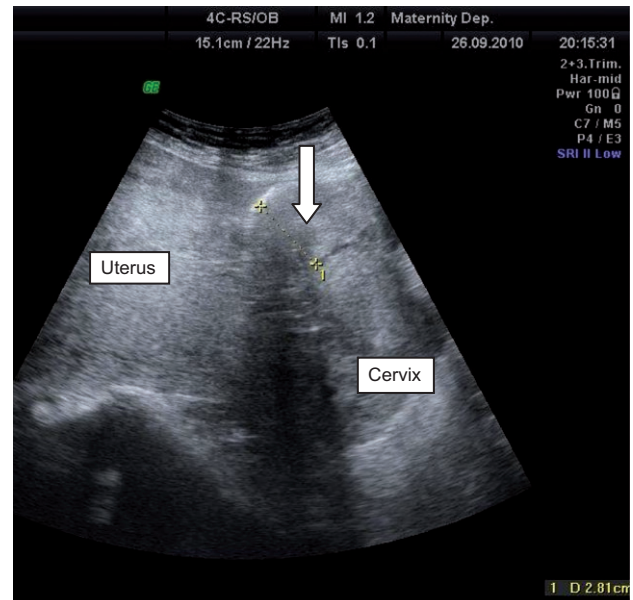


Figure 2 Two-dimensional ultrasound of the uterus demonstrating an irregular hyperechoic area (arrow) at the lower uterine segment, representing possible blood clot covered with the peritoneum. In this case, active bleeding was through the vagina.

Case 2

A 37-year-old G3 P2 woman was admitted to the delivery room with uterine contraction at 39.6 weeks' gestation. Her obstetrical history consisted of one low transverse cesarean section at term at G1 owing to breech presentation, and one vacuum extraction at term owing to non-reassuring fetal monitor at G2.

On admission, her physical examination was unremarkable with soft, non-tender uterus without tenderness on the uterine scar, without bleeding. Her cervix was dilated to 3 cm, 70% effaced, with the fetal head at S-3. She was admitted to the labor room and progressed spontaneously to full dilatation and normal vaginal delivery. The fetal monitor consisted of a baseline of 140 bpm, accelerations, and good variability. In the last 5 min of labor, at full dilatation and during pushing, moderate variable decelerations appeared that preserved good variability, and she gave birth to a 3370 g boy with Apgar scores of 9 and 10 at 1 and 5 min, respectively. Following delivery of the placenta, moderate bleeding appeared. Manual revision of the uterus revealed rupture in the anterior wall of the uterus above the cervix. Abdominal ultrasound demonstrated a hyperechoic area of 28 mm at the area of the uterine scar (Figure 2), with no free fluid in the abdomen. Her vital signs were normal. She was taken to the operation room for explorative laparotomy through the previous Pfannenstiel scar. No blood was seen in the abdominal cavity. Separation of the peritoneum revealed a rupture of 5 cm

in the middle of the previous uterine scar (Figure 3). The urinary bladder was intact. The rupture was repaired. She received blood products and remained hemodynamically stable during the operation. Her follow-up was unremarkable, and she was discharged within 5 days.

Discussion

The concern for uterine rupture is high when VBAC is attempted. The relative risk of uterine rupture during

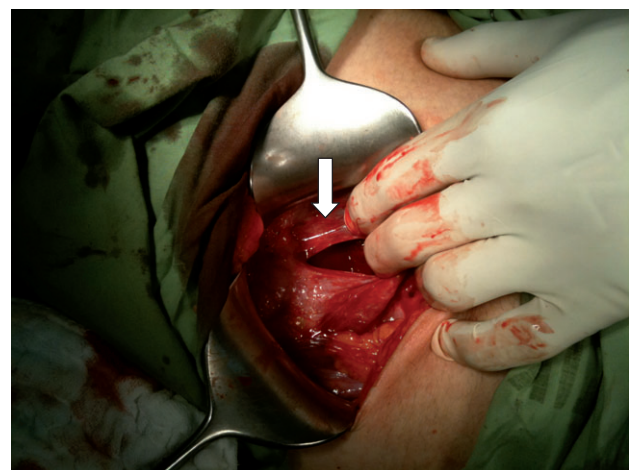


Figure 3 View of the uterine rupture (arrow) of case no. 2.

delivery following a prior cesarean delivery in women with spontaneous onset of labor is 3.3 with an incidence of 5.2 per 1000 [1]. Most cases occur during labor and pose a great risk for both mother and fetus. Usually, emergent laparotomy is performed with no additional evaluation. Therefore, there is little information regarding the sonographic appearance of the ruptured uterus [3, 4].

We described two patients who had previously delivered both vaginally and by cesarean section, and delivered vaginally in the current pregnancy. Manual revision of the uterus performed a few minutes after delivery led to a diagnosis of uterine rupture. In the first case, there was no vaginal hemorrhage, but sonographic evaluation revealed free fluid in the abdominal cavity and uterine rupture appeared as a hypoechogenic area at the lower uterine segment. Consistently, within the entrance to the abdomen, blood was found in the abdominal cavity with complete rupture of the uterus. We assume that

the hypoechogenic area reflects active bleeding into the abdominal cavity.

The clinical presentation of the second case was vaginal bleeding with sonographic findings of hyperechogenic area in the uterine scar with no free fluid in the abdomen. Exploration of the abdomen revealed no blood within the abdomen, with the peritoneum covering the uterine rupture. We assume that the hyperechogenic area reflects clots beneath the peritoneum.

In summary, the sonographic signs of uterine rupture include irregularity in the lower uterine segment. Ultrasound may aid in the diagnosis of active bleeding into the abdomen and may help in the diagnosis of complete vs. incomplete rupture of the uterus, as well as for preparing blood products. We recommend using ultrasound in suspected cases as an additional method to clinical evaluation.

Received August 14, 2011. Accepted November 17, 2011. Previously published online February 25, 2012.

References

- [1] Cunningham FG, Leveno KJ, Bloom SL, Hauth JC, Gilstrap LC, Wenstorm KD. Prior cesarean section. In: Williams obstetrics. 22nd ed. New York: McGraw-Hill; 2005. p. 614–7.
- [2] Cunningham FG, Leveno KJ, Bloom SL, Hauth JC, Gilstrap LC, Wenstorm KD. Obstetrical hemorrhage. In: Williams obstetrics. 22nd ed. New York: McGraw-Hill; 2005. p. 837–9.
- [3] Ogbale GI, Ogunseyinde OA, Akinwuntan AL. Intrapartum rupture of the uterus diagnosed by ultrasound. *Afr Health Sci*. 2008;8:57–9.
- [4] Suonio S, Saarikoski S, Kääriäinen J, Virtanen R. Intrapartum rupture of uterus diagnosed by ultrasound: a case report. *Int J Gynaecol Obstet*. 1984;22:411–3.
- [5] Turner MJ, Agnew G, Langan H. Uterine rupture and labour after a previous low transverse caesarean section. *Br J Obstet Gynecol*. 2006;113:729–32.
- [6] American College of Obstetricians and Gynecologists. Vaginal birth after previous cesarean delivery. *ACOG Practice Bull*. 2004;54.

The authors stated that there are no conflicts of interest regarding the publication of this article.